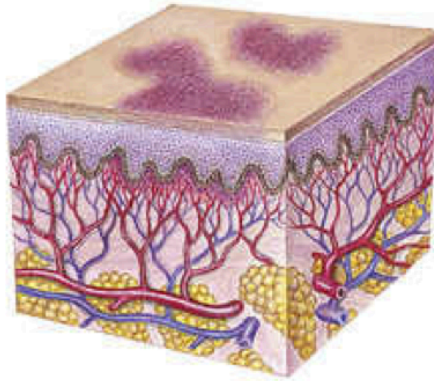
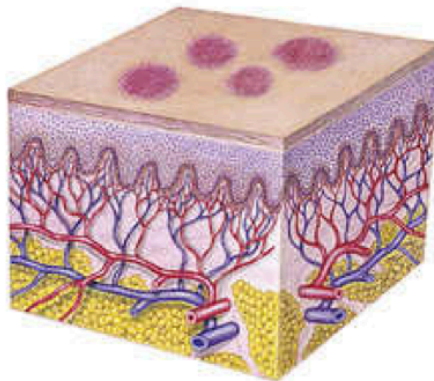


VASCULAR SKIN FINDINGS

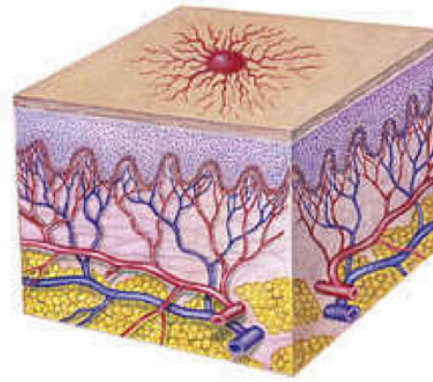
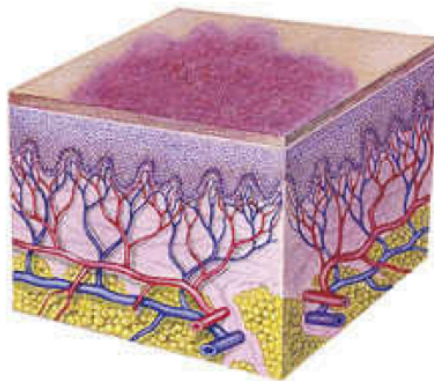
Purpura—red-purple nonblanchable discoloration greater than 0.5 cm in diameter
Cause: Intravascular defects, infection



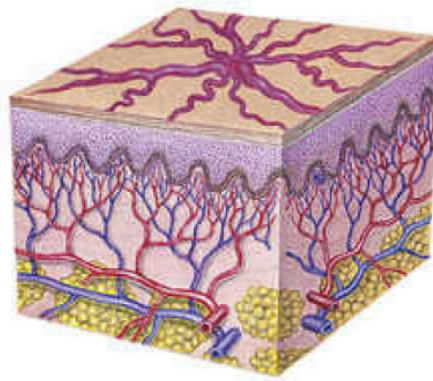
Petechiae—red-purple nonblanchable discoloration less than 0.5 cm diameter
Cause: Intravascular defects, infection



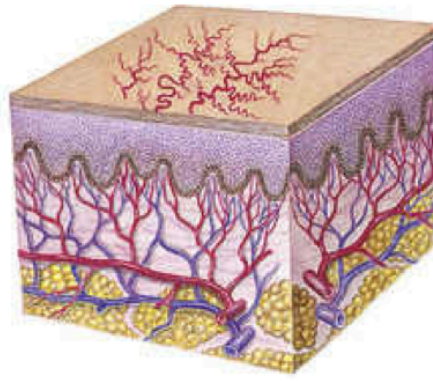
Ecchymoses—red-purple nonblanchable discoloration of variable size
Cause: Vascular wall destruction, trauma, vasculitis



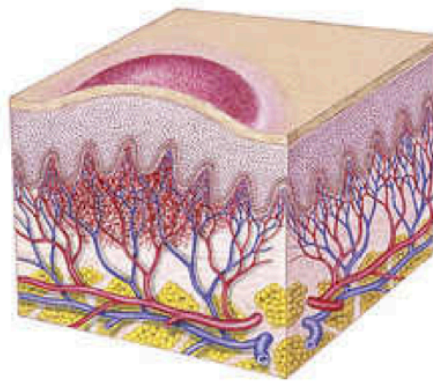
Spider angioma—red central body with radiating spider-like legs that blanch with pressure to the central body
Cause: Liver disease, vitamin B deficiency, idiopathic



Venous star—bluish spider, linear or irregularly shaped; does not blanch with pressure
Cause: Increased pressure in superficial veins



Telangiectasia—fine, irregular red line
Cause: Dilation of capillaries



Capillary hemangioma (nevus flammeus)—red irregular macular patches
Cause: Dilation of dermal capillaries

FIG. 9.9 Characteristics and causes of vascular skin lesions.